

Pulsed Dye Laser Treatment of Multiple Eccrine Hidrocystomas: A Novel Approach

ELIZABETH TANZI, MD AND TINA S. ALSTER, MD

Washington Institute of Dermatologic Laser Surgery, Washington, D.C.

BACKGROUND. Multiple eccrine hidrocystomas are benign cystic lesions that pose a significant treatment challenge due to their facial location and tendency to scar after traditional surgical and other destructive modalities.

METHODS. A 585nm pulsed dye laser was used at fluences ranging 7.0 J/cm² to 7.5 J/cm² at 6- to 8-week intervals to treat multiple lesions on the face of a 54-year-old man.

RESULTS. Near complete resolution of all papules was seen after four laser sessions. There was no evidence of lesional recurrence 18 months after the final treatment.

CONCLUSION. The 585nm pulsed dye laser can effectively treat eccrine hidrocystomas. The mechanism of action whereby this vascular-specific laser produced improvement is unclear.

HIDROCYSTOMAS ARE sweat gland cysts classified into eccrine and apocrine types. First described by Robinson in 1893 in women working in hot, humid environments presenting with multiple facial lesions,¹ eccrine hidrocystomas represent benign cystic dilations of previously normal dermal eccrine ducts.² In 1973 Smith and Chernosky³ described another group of patients who most commonly displayed solitary bluish-hued lesions ranging in size from less than 1 mm to several millimeters. Eccrine hidrocystomas present as tense vesicles or translucent papules most often involving the face, predominantly in a periorbital distribution. Enlargement of the cysts is associated with excessive sweating or increased ambient temperature, presumably due to sweat retention.³⁻⁷ Histopathologically a unilocular cyst with a wall composed of a double layer of small, cuboidal epithelial cells is present within the dermis, often with eccrine secretory tubules and ducts located in close proximity.⁸

While a solitary eccrine hidrocystoma can be treated easily with surgical excision, the elimination of multiple lesions is problematic due to their number and location. Current therapeutic modalities include incision and drainage, surgical excision, and topical anticholinergic medications.⁹⁻¹² We report a case of multiple eccrine hidrocystomas successfully treated with a 585 nm flashlamp-pumped pulsed dye laser.

Methods

A 54-year-old man presented with a 5-year history of numerous small, pale-blue papules on his lower eyelids and cheeks (Figure 1). The lesions were exacerbated by exercise, sun exposure, and extreme elevation of temperature and were cosmetically unappealing to the patient, prompting him to seek treatment. Findings on tissue biopsy were consistent with eccrine hidrocystoma (Figure 2).

Treatment was initiated with a 585 nm flashlamp-pumped long-pulsed (1.5 msec) dye laser using a 7.0 mm spot size at a fluence of 7.0 J/cm², producing an immediate purpuric tissue response. Postoperative wound care consisted of daily cleansing with mild soap and water followed

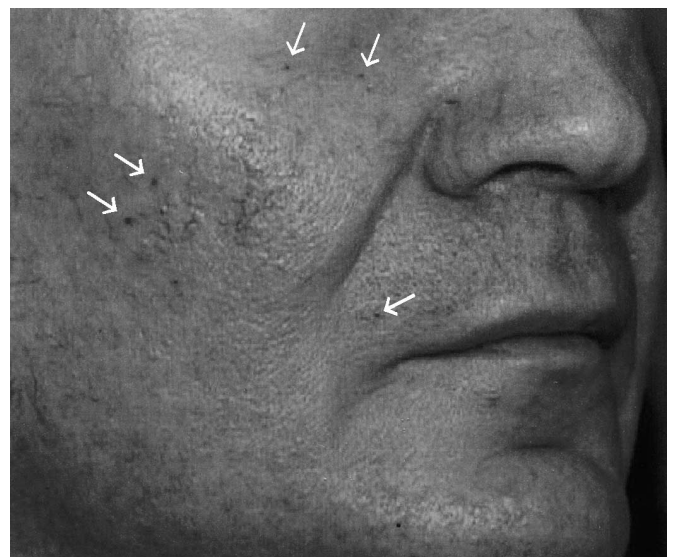

Figure 1. Multiple bluish-hued papules are present on the cheeks and infraorbital regions. The patient reported lesional enlargement with exercise or upon exposure to sun or humidity.

E. Tanzi, MD and T.S. Alster, MD have indicated no significant interest with commercial supporters.

Address correspondence and reprint requests to: Tina S. Alster, MD, 2311 M St. NW, Suite 200, Washington, DC 20037, or e-mail: talster@skinlaser.com.

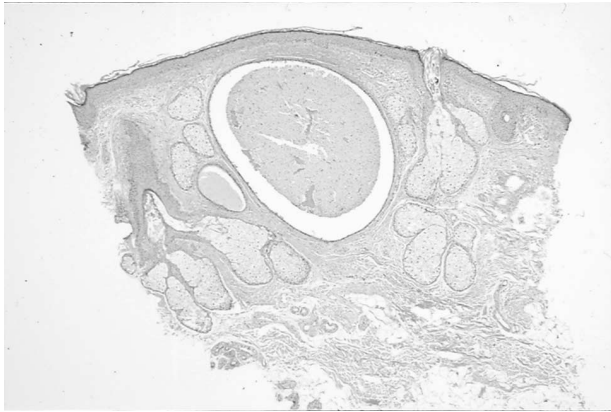


Figure 2. A unilocular dermal cyst with a wall composed of a double layer of cuboidal cells confirmed the diagnosis of eccrine hidrocystoma.

by application of topical antibiotic ointment until purpura resolved (5–7 days). Examination 2 months after the initial treatment revealed significant fading of lesional color and reduction of cyst size (Figure 3). After three additional treatments applying fluences of 7.0–7.5 J/cm² at 6- to 8-week intervals, there was near-complete resolution of the lesions. No lesional recurrence was noted 18 months after the fourth laser treatment (Figure 4).

Conclusion

Multiple eccrine hidrocystomas are benign cystic lesions associated with a chronic course and seasonal variability. Their presence may be cosmetically unde-

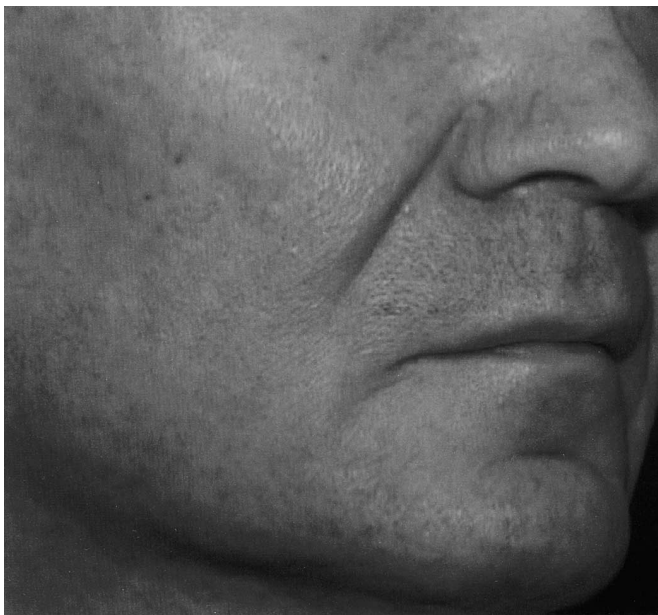


Figure 3. After one 585 nm pulsed dye laser treatment at 7.0 J/cm² (7 mm spot), significant lesional fading was seen.

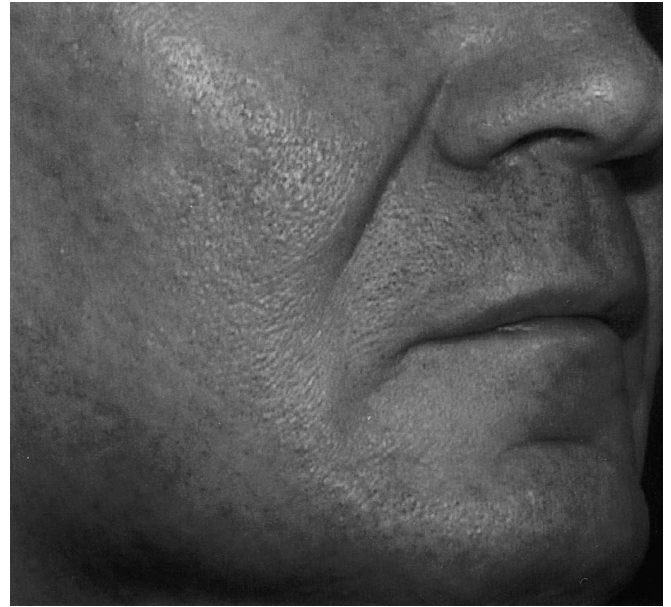

Figure 4. Complete lesional eradication was achieved after a total of four PDL treatments (fluences 7.0–7.5 J/cm²) without evidence of recurrence 18 months postoperatively.

sirable, as well as psychosocially distressing as a result of their predominately facial location.

Multiple eccrine hidrocystomas pose a significant treatment challenge to the cutaneous surgeon, with the number and location of the lesions precluding the usefulness of surgical excision. Complete excision or aggressive destruction may lead to unacceptable scarring. Lesional incision and drainage provides a temporary solution; however, recurrences are often observed within 4–6 weeks. Although the use of topical atropine (scopolamine) has been shown to offer clinical improvement, anticholinergic side effects have been reported and results have been variable.^{10–12} The benefits of pulsed dye laser treatment for multiple eccrine hidrocystomas include ease of application, minimal risk of scarring, and an uncomplicated postoperative course. Disadvantages include the need for multiple treatments, with possible greater financial expense incurred by the patient.¹³

The mechanism whereby a vascular-specific 585 nm pulsed dye laser produced improvement in this patient is unclear; however, this report indicates that multiple eccrine hidrocystomas may be treated effectively and safely without lesional recurrence 18 months after a series of pulsed dye laser treatments. Further long-term evaluation will be needed to determine if the favorable results observed in this patient are permanent.

References

1. Robinson AR. Hidrocystoma. *Journal of Cutaneous and Genitourinary Disease* 1893;11:293–303.

2. Sperling JD, Sakas EL. Eccrine hidrocystomas. *J Am Acad Dermatol* 1982;7:763-70.
3. Smith JD, Chernosky ME. Hidrocystomas. *Arch Dermatol* 1973;108:676-9.
4. Ebner VH, Eblach E. Ekkrine hidrozystome. *Dermatol Monatsschr* 1975;161:739-44.
5. Bourke JF, Colloby P, Grahm-Brown RA. Multiple pigmented eccrine hidrocystomas. *J Am Acad Dermatol* 1996;35:480-82.
6. Kato N, Ueno H. Eccrine hidrocystoma: two cases of Robinson and Smith types. *J Dermatol* 1992;19:493-7.
7. Murayama N, Tsuboi R, Unno K, Ogawa H. Multiple eccrine hidrocystomas. *Br J Dermatol* 1994;131:585-6.
8. Elder D, Elenitsas R, Jaworsky C, Johnson B, eds. *Lever's histopathology of the skin*, 8th ed. New York: Lippincott-Raven, 1997:778.
9. Dostrovsky A, Sagher F. Experimentally induced disappearance and reappearance of lesions of hidrocystomas. *J Invest Dermatol* 1942;5:167-72.
10. Masri-Fridling GD, Elgart ML. Eccrine hidrocystomas. *J Am Acad Dermatol* 1992;26:780-82.
11. Clever HW, Sahl WJ. Multiple eccrine hidrocystomas: a non-surgical treatment. *Arch Dermatol* 1991;127:422-3.
12. Armstrong DKB, Walsh MY, Corbett JR. Multiple facial eccrine hidrocystomas: effective topical therapy with atropine. *Br J Dermatol* 1998;139:558-9.
13. Alster TS. *Manual of cutaneous laser techniques*, 2nd ed. Philadelphia: Lippincott Williams & Wilkins, 2000:33-52.